

Postpartum Peripheral Symmetrical Gangrene: A Case Report

Lipi Sharma^{1*}, Sumita Mehta¹, Shalini Rajaram¹, Rachna Aggarwal¹, Sanjay Gupta², Neerja Goel¹

1- Department of Obstetrics and Gynecology, University College of Medical Sciences and Associated Guru Teg Bahadur Hospital, Shadara, India

2- Department of Surgery, University College of Medical Sciences and Associated Guru Teg Bahadur Hospital, Shadara, India

Abstract

Background: Symmetrical peripheral gangrene is usually associated with underlying medical problems and it is seldom seen in pregnancy. Sepsis though common in a setting of delivery by unskilled midwife is rarely accompanied by symmetrical gangrene.

Case Presentation: We report a case of symmetrical peripheral gangrene which occurred in the winter, triggered possibly by sepsis and a single dose of ergot. A high index of suspicion, early diagnosis and intervention with appropriate measures will result in favorable outcome in such cases.

Conclusion: Although postpartum period is of high risk for sepsis and use of ergot alkaloids is common in labor but occurrence of peripheral symmetrical gangrene is rare. A high index of suspicion for the diagnosis and timely intervention will prevent irreparable damage and loss of limb.

Keywords: Ergot, Peripheral symmetrical gangrene, Postpartum.

To cite this article: Sharma L, Mehta S, Rajaram Sh, Aggarwal R, Gupta S, Goel N. Postpartum Peripheral Symmetrical Gangrene: A Case Report. *J Reprod Infertil.* 2012;13(2):117-119.

* Corresponding Author:
Lipi Sharma, Senior
Resident, 22, doctors
apartment,
vasumdhara enclave,
Delhi-110096
E-mail:
lip.sharma14@gmail.com

Received: Aug. 6, 2011

Accepted: Oct. 19, 2011

Introduction

Despite the frequent use of ergots and settings of sepsis, we rarely encounter peripheral symmetrical gangrene in pregnant women. Whether it is because of physiological changes in the peripheral vascular system during pregnancy (increased plasma volume, decreased plasma osmolality and decreased peripheral resistance) that actually offset a severe vasospasm is not fully understood?

We present a case of symmetrical peripheral gangrene which occurred in the winter, triggered possibly by sepsis and a single dose of ergot.

Case Presentation

A 25-year old P1L1 woman presented to the emergency two day post partum with bluish discoloration of hands and feet. Pregnancy had been unsupervised but she had received tetanus immunization. Delivery had been conducted at home by an unskilled midwife and she had been administered a single intramuscular injection of ergot

postpartum. There was no prior history of intermittent claudication, cold or heat intolerance, tobacco smoking, collagen vascular disease or similar family history. Vitals were stable, all peripheral pulses were palpable. Extremities were cold, swollen with purple discoloration of both hands extending to wrist joints. Similar changes were seen in feet extending to mid calf. Both hands and feet had blue-black nail beds. On per abdominal examination a well contracted uterus corresponding to 20 weeks gravid size was felt. On local examination, a complete perineal tear with black gangrenous margins and excoriation was present; similar patchy changes were seen over lower abdomen and the mons pubis. Internal examination was normal. A differential diagnosis of early gangrene was made.

On investigation her Hb was 9 g/dl, total leukocyte count (TLC) 18,000/mm³, platelet count 250,000/mm³; liver function tests: (LFT) serum bilirubin (t) 8 mg/dl, ALT/AST 28/25 and kidney

function tests: (KFT) serum creatinine 0.6 mg/dl and blood urea 11 mg/dl. On sepsis work-up, her blood and urine cultures were sterile and culture taken from perineal wound had no pathogenic growth. The patient's ELISA for HIV was negative and VDRL was non-reactive. On coagulation screen her PT was 12 s and PTTK 32 s. On transvaginal ultrasonography uterine cavity was empty. Patient was further investigated for all possible causes of peripheral gangrene which included antiphospholipid antibody testing (ACL Ig G and Ig M and LAC which all were negative), lipid profile (Serum chol sterol 140 mgs/dl, Serum TG 110 mg/dl, HDL-chol 40 mg/dl), antinuclear antibody and rheumatoid factors were negative too. Color Doppler of lower limb vessels was done which indicated normal flow.

Surgical consultation was sought and perineal wound debrided. Therapy in the form of broad spectrum antibiotics, low molecular weight dextran and a hemorheologic agent, pentoxifylline, was started. By day five, improvement was noted with subsidence of swelling and sharp demarcation of margins (Figure 1). Patient lost most nails of both hands and feet by day 28, gangrenous scabs were shed from tips of fingers while the toes still had scabs (Figure 2). Patient was discharged on pentoxifylline, with advice on the care of hands and feet. By six weeks there was regrowth of nails but scabs on feet remained. By eight weeks hands, feet and mons pubis appeared normal.

Discussion

Our patient was young with no prior evidence of major occlusive disease, connective tissue disorder or any other identifiable cause for gangrene. She developed peripheral symmetrical gangrene in January after being delivered at home by an unskilled midwife. Although sepsis could not be documented despite a thorough workup, we feel this phenomenon along with the cold and an injection of probably an ergot could have offset the

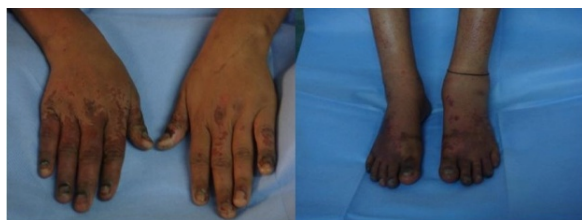


Figure 1. Sharp demarcation of normal from abnormal areas by day 5

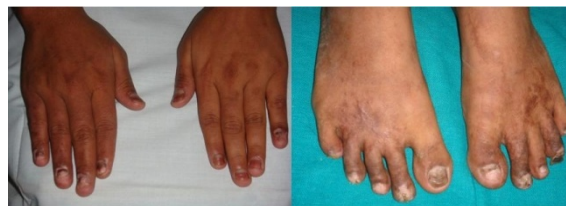

Figure 2. Shedding of hand and feet nails in 4 weeks

process of gangrene.

A high index of suspicion, early diagnosis and intervention with appropriate measures which included debridement of perineal wound limited progression of gangrene to just loss of nails, which eventually grew back. Although sporadic reports of postpartum gangrene in pregnancy have been reported, these have been mainly due to underlying vascular occlusive disorders or following abortions induced by ergots (1–5). A recent report evaluated 14 patients with symmetrical peripheral gangrene and found sepsis to be a major cause with a high amputation rate and mortality (6). In our case no clear cause could be defined.

We present this case to highlight the importance of identifying and treating pregangrenous changes in limbs early enough to avoid amputation. This is also the first time when images capturing the sequence of changes from onset of gangrene to localization of a spreading phenomenon, shedding of nails and scabs to final reparative changes leading to regrowth of nails and normal appearance of limbs is shown. During the regenerative process meticulous care of the affected areas is needed to prevent infections and ensure a favorable outcome.

Conclusion

Although postpartum period runs a high risk for sepsis and use of ergot alkaloids is common in labor, but occurrence of peripheral symmetrical gangrene is rarely seen in this period. Peripheral symmetrical gangrene is a life-threatening condition which warrants early diagnosis and prompt treatment, any delay to do so may leave sequelae which vary from amputation to death.

References

1. Avrech OM, Golan A, Pansky M, Langer R, Caspi E. Raynaud's phenomenon and peripheral gangrene complicating scleroderma in pregnancy--diagnosis and management. *Br J Obstet Gynaecol.* 1992;99 (10):850-1.

2. Smith CA, Pinals RS. Progressive systemic sclerosis and postpartum renal failure complicated by peripheral gangrene. *J Rheumatol.* 1982;9(3):455-8.
3. Dam AK, Mishra JC. Managing ergot-induced gangrene: the anesthesiologist as a key player. *Anesth Analg.* 2002;95(2):409-10.
4. Ghosh SK, Bandyopadhyay D, Ghosh A. Symmetrical peripheral gangrene: a prospective study of 14 consecutive cases in a tertiary-care hospital in eastern India. *J Eur Acad Dermatol Venereol.* 2010;24(2):214-8.