

The Protective Effect of Vitamin E on Morphological and Biochemical Alteration Induced by Pre and Postnatal Ethanol Administration in the Testis of Male Rat Offspring: A Three Months Follow-up Study

Alireza Shirpoor^{1*}, Leila Norouzi¹, Mohammad-Hasan Khadem-Ansari², Behrouz Ilkhanizadeh³, Mojtaba Karimipour⁴

1. Department of Physiology, Faculty of Medicine, Urmia University of Medical Sciences, Urmia, Iran

2. Department of Biochemistry, Faculty of Medicine, Urmia University of Medical Sciences, Urmia, Iran

3. Department of Pathology, Faculty of Medicine, Urmia University of Medical Sciences, Urmia, Iran

4. Department of Anatomy, Faculty of Medicine, Urmia University of Medical Sciences, Urmia, Iran

Abstract

Background: Dysmorphology and dysfunction caused by prenatal ethanol consumption in different organs of the offspring are wellknown phenomena. The objective of the present study was to explore the antioxidant effect of vitamin E supplementation on testis damage induced by maternal ethanol consumption during pregnancy and early postnatal days.

Methods: Pregnant Wistar rats on gestation day 7 were assigned to 3 groups, namely, control, ethanol and ethanol-vitamin E groups. Ethanol-treated rats received 4.5 g/kg BW ethanol once per day from day 7 and the procedure continued through postnatal day 21. Vitamin E group received 300 mg of vitamin E and the same amount of ethanol. The male offspring from each group were anesthetized by 10% chloral hydrate (0.5 ml/kg body weight) on day 21 and 90 (n=8 offspring from each group on day 21 and day 90). The results were analyzed by one-way ANOVA. A $p < 0.05$ was considered significant.

Results: The results revealed significant ($p < 0.05$) changes in oxidative stress parameters, luteinizing hormone and follicle-stimulating hormone, as well as testis structural alteration in offspring of ethanol group after 21 and 90 days of birth as compared to the control. Significant amelioration of changes in testis structure, along with restoration of the elevated level of oxidative stress parameters were found in vitamin E-treated animals.

Conclusion: The findings revealed that prenatal and postnatal ethanol-induced toxicity in testis was exerted through oxidative stress and implied that these effects could be alleviated by vitamin E as an antioxidant.

Keywords: Ethanol, Oxidative stress, Rat, Testis, Vitamin E.

To cite this article: Shirpoor AR, Norouzi L, Khadem-Ansari MH, Ilkhanizadeh B, Karimipour M. The Protective Effect of Vitamin E on Morphological and Biochemical Alteration Induced by Pre and Postnatal Ethanol Administration in the Testis of Male Rat Offspring: A Three Months Follow-up Study. *J Reprod Infertil.* 2014;15(3):134-141.

* Corresponding Author:
Alireza Shirpoor,
Department of Physiology,
Faculty of Medicine,
Urmia University of
Medical Sciences, Urmia,
Iran
E-mail:
ashirpoor@yahoo.com

Received: Feb. 10, 2014

Accepted: Jul. 8, 2014

Introduction

The disorders associated with ethanol drinking during pregnancy have been well documented and are named fetal alcohol spectrum disorder (FASD) (1). These disorders consist of a wide spectrum of effects like craniofacial dys-

morphology, growth retardation, as well as neurodevelopmental and cognitive deficits (2). Perhaps the most devastating sequels of FASD are the neurobehavioral manifestations associated with the effect of alcohol on the central nervous system

(3); however, recent studies have shown that ethanol drinking during pregnancy causes dysgenesis of many organ systems, such as gastrointestinal tract, cardiovascular and reproductive systems (4-6). Previous studies have shown that fetal alcohol exposure alters the function of reproductive system and androgen dependent behaviors in both male and female rats. Evidence exists that male rats who are prenatally exposed to ethanol demonstrate elevated levels of female sexual behavior, demasculinized behavior, decreased testicular steroid production, reduced testis weight and reduced sperm count in their adulthood (7-10). In females, prenatal ethanol exposure delays sexual maturation (*i.e.* vaginal opening), decreases hypothalamic pituitary gonadal (HPG) axis function and disrupts normal menstrual cycling in female human as well (11-13).

Although the precise cellular and biochemical causes of prenatal ethanol exposure-induced susceptibility to reproductive system disorders have not yet been defined, considerable evidence indicates that maternal ethanol consumption during pregnancy and oxidative stress in early postnatal period play a critical role in ethanol susceptibility to reproductive system disorders. Furthermore, many ethanol-induced adverse effects can be prevented or attenuated by antioxidants (14).

It was recently found that ethanol administration, in both male adult rats and pregnant female rats, results in oxidative stress and inflammatory changes in the hippocampus and aortic walls which are manifested by increased protein oxidation, lipid peroxidation, and pro-inflammatory cytokines including CRP, IL-6 and haptoglobin (15, 16). Since such cytokines and oxidative stress parameters have deleterious effects on ethanol induced disorders in different organs, it seems possible that the deleterious effect of prenatal ethanol consumption could be due, at least in part, to this oxidative stress. In addition, the antioxidant vitamin E was used in this study as a tool to determine whether reducing oxidative stress protects the reproductive system from the impact of ethanol consumption by the mother during pregnancy and early postnatal days.

Methods

All procedures for utilizing rats were carried out in accordance with the National Institutes of Health Guidelines for the Care and Use of Laboratory Animals and were approved by the Urmia University of Medical Sciences, Animal Care

Committee. Adult female Wistar rats weighing 200 ± 20 g were kept under a 12:12 hr light/dark cycle, with controlled temperature (23 to 25) and ad libitum access to standard laboratory chow and water. The rats were bred overnight with males previously tested as fertile and were checked for the presence of vaginal plugs the next morning. The presence of a vaginal plug was considered to be indicative of conception and that hour was designated as day 0 of gestation (GD0). On gestation day (GD) 7, the females were singly housed and randomly assigned to 3 groups, namely, control, ethanol and ethanol-vitamin E group.

Ethanol-treated rats received 4.5 g/kg BW ethanol (Merck KGaA, Darmstadt, Germany) solution in normal saline (20% w/v) intragastrically by gavage once a day from GD7 and the procedure continued through postnatal (PN) day 21 (lactation period). According to our preliminary studies, rats in the VETE group received a non-toxic dose of 300 mg of vitamin E (Merck GmbH, Germany) intragastrically by gavage in addition to their regular daily diet and the same amount of ethanol. The control group was treated with vehicle only (normal saline). Following their birth, some litters were culled to reduce their number to 3 or 4 male pups/mother. This was done to decrease possible nutritional deficiencies due to competition among the litters. The male offspring from each group were anesthetized by 10% chloral hydrate (0.5 ml/kg body weight) on PN21 and 90 (n=8 offspring from each group on PN21 and PN90).

After weighing, the thoracic cavity was opened and blood sample was collected directly from the heart by syringe and was mixed with ethylenediaminetetraacetic acid (EDTA) as an anticoagulant. It was then centrifuged at $4000 \times g$ for 20 min within 30 min of collection. Next, the plasma was separated and stored at -80°C without repeated freeze-thaw cycles. After blood sampling, abdomen of each animal was opened and the testis was removed and weighed at the time of termination. In the end, a part of the right testis was fixed in buffered formalin and embedded in paraffin, after taking standard dehydration steps.

Some sections of the testis were washed with ice-cold physiological saline solution, then dried and processed for biochemical measurements. The tissues were homogenized and then centrifuged at $10,000 \times g$ for 20 min at 4°C in a refrigerated centrifuge using Ultra Turrax (T10B, IKA, Germany) homogenizer in an ice-cold extraction buffer (10% wt/vol) containing 50 mM phosphate buffer (pH=

7.4). The supernatant sample was collected and stored at -80°C until the time of analysis, without a repeated freeze-thaw cycle.

Biochemical assay:

Ox-LDL: Tissue Ox-LDL levels were measured using a capture rat ELISA (also known as a "sandwich" ELISA) kit, in which the wells of the microtiter plates were coated with the capture antibody mAb-4E6 (Mercoxia, Sweden). Diluted supernatant samples (1:6561) were used for ELISA measurements. The optical density of the wells was read at 450 nm and the results were calculated.

Protein carbonyl: Protein carbonyl content was measured in the supernatant samples using a protein carbonyl assay kit (Cayman chemical, Ann Arbor, USA); briefly stated, 2, 4-dinitrophenylhydrazine (DNPH) reacted with protein carbonyl forming a Schiff base to produce the corresponding hydrazone which can be analyzed spectrophotometrically. Due to methodology of the assay, the protein carbonyl assay reacted with carbonyls from both protein and lipid. To discriminate between the two, a trichloroacetic acid (TCA) precipitation step was performed in the protein carbonyl assay to precipitate the proteins pelleted by centrifugation, followed by two ethanol/ethyl acetate wash steps that would effectively remove lipids from the protein pellet. Therefore, the signal from the assay would only come from protein carbonyls, not from lipid carbonyls.

Total antioxidant capacity: The total antioxidant capacity of tissue lysates was calculated using antioxidant assay kit (709001, Cayman Chemicals, USA). The assay relied on the ability of antioxidants in the sample to inhibit the oxidation of ABTS (2, 2'-Azino-di-[3-ethylbenzthiazoline sulphinate]) to ABTS^{•+} by metmyoglobin. It also measured all aqueous- and lipid-soluble antioxidants (including vitamins, proteins, lipids, glutathione, uric acid, etc.). The capacity of the antioxidants in the sample was compared with that of Trolox, a water-soluble tocopherol analogue in terms of prevention of ABTS oxidation. Furthermore, it was quantified as millimolar Trolox equivalents. The results were normalized by total protein content of each tissue sample. Detection range of the kit was 0.044-0.330 mM.

Total protein: The total protein concentration was determined by applying the method of Bradford (Bradford, 1976), using bovine serum albumin as the standard.

Gonadotrophin and androgen hormones: Gonadotrophin and androgen hormones assay were carried out by chemiluminescence immunoassay technology using a specific antibody for each hormone.

Briefly, all tests were measured by a photomultiplier as the relative light unit and it was indicative of a luteinizing hormone (LH), follicle stimulating hormone (FSH), testosterone, and dehydroepiandrosterone sulfate (DHEAs) concentrations present in the samples, as compared with standard curve and reagents used as a cartridge system by Diasorin company (Diasorin, Saluggia, Italy). Furthermore, experiments were performed with Liaison automated chemiluminescence analyzers (Liaison, BYK, Sangtec, Spain) and all the tests were carried out with quality controls.

Histopathological examinations: A series of 5 μm thick sections of formalin fixed paraffin embedded (FFPE) testis tissue was used for histopathological staining. The general structure of the testis and morphological changes were examined using Harris' Hematoxylin and Eosin (H&E) Staining Protocols. To determine the glycogen content of the testis tissue, the slides were subjected to Periodic Acid-Schiff (PAS) stain procedure, in accordance with the kit instructions.

Seminiferous tubule diameter measurement was carried out using a linear scale-ocular micrometer inserted into the eyepiece.

Statistical analysis: Statistical differences between the groups were tested by one-way ANOVA, followed by Tukey's post hoc test. In each test, the data are expressed as the mean \pm S.E.M. In addition, $p < 0.05$ was considered statistically significant.

Results

Impact of pre and postnatal ethanol consumption on the offspring body and testis weight: Separate analyses of the offspring body weight on PN21 and PN90 are shown in table 1. The body weight of pups from the ethanol-treated rats were significantly lower than those of the control group on PN21 ($p < 0.005$). Although body weight in the vitamin E-treated group was significantly higher than that in the ethanol-treated group, it was still significantly lower as compared to the one in the control group on PN21 ($p < 0.05$). On PN90, the body weights of pups belonging to the ethanol and ethanol-vitamin E-treated groups were significantly higher than those in the control group ($p < 0.005$). The analysis of the male offspring testis

Table 1. The changes of body weight (gr) and testis weight in different groups

	Control PN21	Ethanol PN21	Vitamin E PN21	Control PN90	Ethanol PN90	Vitamin E-PN90
Testis-w-R	0.147±0.002	0.076±0.008 *	0.081±0.006 **	1.4±0.068	1.46±0.051	1.48±0.027
Testis-w-L	0.151±0.002	0.075±0.005 *	0.083±0.007 **	1.48±0.03	1.55±0.04	1.55±0.04
Tot-testis-w	0.298±0.003	0.151±0.01 *	0.156±0.01 **	2.88±0.9	3±0.09	3±0.06
B.W	47.4±0.71	25.16±1.3 *	29.6±1.48 **	236.8±4.8	264±3.3 *	271±4.9 **
T.W/B.W	6.3±0.1	5.96±0.29	6.13±0.18	12.17±0.82	11.39±0.68	11.21±0.77

Values expressed as mean±SEM, significant differences at p<0.05

*Significant difference compared to the control; ** Significant difference compared to the ethanol

Testis-w-R: testis weight right; Testis-w-L: testis weight left; B.W: body weight; tot-testis w: total testis weight; T.W/B.W: testis weight/body weight

weights during postnatal stages (PN21 and PN90) indicated a trend for an early prenatal group effect. Furthermore, a significant main effect of PN21 was observed in the ethanol-treated and ethanol-vitamin E-treated groups. The testis weight in both the ethanol and ethanol-vitamin E-treated groups was significantly lower than that in the control group (p<0.05). However, by comparing the ethanol-treated and ethanol-vitamin E-treated groups, it was found that vitamin E administration increased the testis weight significantly in the vitamin E-treated group as compared to the ethanol-treated group (p<0.05). On PN90, there was no significant difference between the testis weights in different groups. The testis weight/body weight ratio analysis showed that there were no significant differences between different groups on PN21 and PN90 (Table 1).

Serum gonadotropin and androgen hormone levels: No significant differences were found between different groups regarding LH levels on the early postnatal day (PN21) and late postnatal day (PN90). On the early postnatal day, FSH levels did not change significantly in different groups. FSH levels decreased significantly on PN90 in the ethanol-treated group as compared to the control group (p<0.05), but no significant differences were found between the ethanol-vitamin E and control group.

Ethanol consumption did not affect testosterone levels significantly on the early PN21 in different

groups. In the late stage of postnatal day, testosterone levels showed a significant decrease in the ethanol and ethanol-vitamin E-treated groups as compared to the control group (p<0.005).

Dehydroepiandrosterone sulfate levels were not measured on PN21. On PN90, the DHEAS level was significantly lower than that in the control group (p<0.05), but it was restored to normal status in the ethanol-vitamin E-treated group (table 2).

Impact of pre and postnatal ethanol consumption on oxidative stress markers: The testis protein carbonyl status in different experimental groups is shown in table 2. In the ethanol-treated group, protein carbonyl amount showed a significant increase on PN21 as compared to the control group (p<0.005). Administration of vitamin E along with ethanol, significantly decreased the amount of protein carbonyl (p<0.05), but it was still significantly higher than the amount in the control group (p<0.05). When compared with the control, the Ox-LDL amount of the testis tissue significantly increased in ethanol-treated rats on PN21 (p<0.005). However, the amount of Ox-LDL was restored after treatment with vitamin E. Maternal ethanol consumption was found to cause a significant decrease in the total antioxidant capacity in the testis tissue of the offspring on PN21 as compared to that in the control group (p<0.005). Treatment with vitamin E along with ethanol increased the total antioxidant capacity of the group significant-

Table 2. The changes of gonadotropins and androgen hormones in different groups

	Control PN21	Ethanol PN21	Vitamin e PN21	Control PN90	Ethanol PN90	Vitamin E-PN90
LH	0.18±0.005	0.16±0.008	0.158±0.009	0.225±0.025	0.2	0.2
FSH	0.19±0.02	0.22±0.01	0.2±0.036	0.364±0.025	0.254±0.003*	0.348±0.04
DHEAS				1.45±0.24	0.93±0.02*	1.1±0.1
Testester on	0.3±0.04	0.46±0.11	0.3±0.07	14.61±0.7	8.26±0.4*	8.22±0.12**

Values expressed as mean±SEM, significant differences at p<0.05; *Significant difference compared to the control; ** Significant difference compared to the ethanol

Table 3. One-way ANOVA considering the effect of the ethanol and vitamin E treatment on data related oxidative stress

	Control-PN21	Ethanol-PN21	Vitamin E-PN21
Protein carbonyl μ g	6.31 \pm 0.71	26.3 \pm 3.3 *	19.91 \pm 2 **
Ox-LDL	22.66 \pm 0.88	34.5 \pm 5.35 *	26.33 \pm 0.66
Total antioxidant	0.136 \pm 0.017	0.0512 \pm 0.006 *	0.27 \pm 0.07 **

Values expressed as mean \pm SEM, significant differences at $p < 0.05$; *Significant difference compared to the control; ** Significant difference compared to the ethanol

ly as compared to that of the group treated with ethanol alone and the control group on PN21 ($p < 0.05$) (Table 3).

Histology of testis: Seminiferous tubule diameters of the offspring on PN21 were 141 ± 1 , 100 ± 1.4 , and $127 \pm 1.8 \mu\text{m}$ in the control, ethanol, and ethanol-vitamin E-treated group, respectively. On PN90, seminiferous tubule diameters were 315 ± 9.5 , 287 ± 9 , and 306 ± 5.2 micrometers in the control, ethanol, and ethanol-vitamin E-treated group, respectively. In both the early and late postnatal days, tubule diameters were significantly lower in the ethanol-treated group as compared to the control group ($p < 0.005$), but it was restored to normal status in the ethanol-vitamin E-treated group. Furthermore, histopathological changes such as vacuolization of germ cells with glycogen droplet and a lower density of Leydig and Sertoli cells were seen in the ethanol-treated group and not in the control group (Figures 1 and 2). In addition, primordial germ cells of the offspring on PN90 in the ethanol-treated group were located close to the membrane with more chromatin clumping in genocytes which indicated less activation and

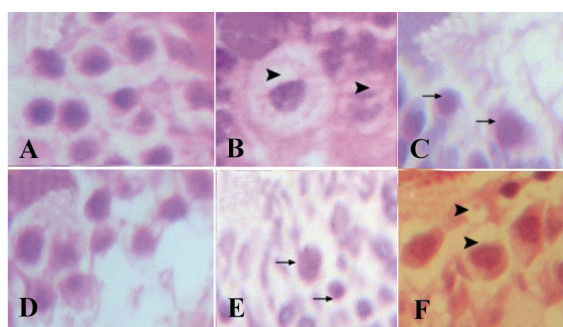


Figure 1. Morphological changes in the testis of different groups. Ethanol consumption induced an increase in glycogen droplet and vacuolization of testis tissue. Vitamin E treatment along ethanol consumption alleviated the structure changes. A: control 21 day, H&E staining; B: ethanol PN 21 H&E staining; C: ethanol PN 21 PAS staining; D: ethanol-vitamin E PN 21 H&E staining; E: ethanol PN 90 PAS staining; F: ethanol PN 90 H&E staining (▶) cell vacuolization, (→) glycogen droplet (Magnification $\times 400$)

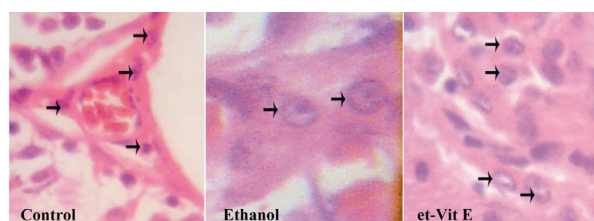


Figure 2. Photomicrograph showing the density of Leydig cells in different groups (▶) Leydig cells (Magnification $\times 400$)

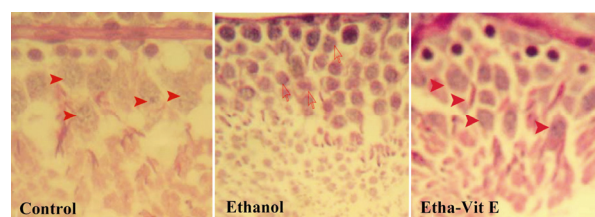


Figure 3. Histopathology of testis tissue in control, ethanol rats, and ethanol-vitamin E rats (hematoxylin-eosin, original magnification $\times 400$). (Control) Control testis tissue with normal genocytes location undergoing mitosis division. (Ethanol) ethanol testis tissue showed that primordial germ cells were located close to membrane with more chromatin clumping in genocytes which indicates less activation and preparation of genocytes for the mitosis process. (etha-Vit E) the morphology of the ethanol-vitamin E-treated group was similar to that of the control group (→) normal cell activation and division, (▶) more chromatin clumping in genocytes

preparation of genocytes for the mitosis process. The morphology of the ethanol-vitamin E-treated group was similar to that of the control group (Figure 3).

Discussion

After ethanol consumption by the mothers during pre and postnatal days, an increase in the oxidative stress markers such as Ox-LDL and protein carbonyl and a parallel decrease in the total antioxidant capacity was observed in early postnatal days in the offspring. In addition, the levels of FSH, DHEAs, and testosterone obtained from PN90 offspring decreased in the ethanol group as

compared to the control group. Furthermore, the testis and body weights in the early postnatal days were also low in the offspring of ethanol-treated group. Histopathological changes such as vacuolization of germ cells with glycogen droplet, low density of Leydig and Sertoli cells as well as more chromatin clumping in genocytes as an indicator for less activation and preparation of genocytes for mitosis, were also found in the offspring's testis of ethanol-treated group as compared to the control group. Significant amelioration of the testis structural changes, as well as restoration and amelioration of levels of oxidative stress markers, and levels of gonadotrophin hormone were found in vitamin E-treated rats as opposed to the ethanol rats.

Although a limited number of studies have shown that maternal ethanol intake induces alterations in some measures of structural and physiological changes in the reproductive system such as lower sperm concentration, reduced preovulatory-like LH surge, reduced surge of testosterone, lower testis weight, and lower percentage of tubules with open lumina, to our best knowledge, this is the first report of a combined in utero and pre-weaning experiment that indicates ethanol consumption during reproductive system development results in structural and hormonal changes with a parallel increase in oxidative stress markers in the offspring testis in early and late period. Previous studies have demonstrated that ethanol intake by pregnant females results in the elevation of blood ethanol levels 150 to 190 mg/dl and a parallel decrease in the body weight throughout gestation and immediately following parturition as compared with ad libitum-fed control dams. However, a fairly rapid catch-up weight gain was observed at the end of the first week of lactation (17, 18). The reduction in body weight was the result of reduced food intake in ethanol-treated dams. It should also be noted that ethanol-derived calories are often "empty calories" in that they replace the calories from food which contains the necessary nutrients (19). In the current study, the offspring body weights and testis weights were also low and adversely affected by pre and postnatal exposure to ethanol on PN21 of parturition. Some previous studies have shown adverse effects of prenatal ethanol consumption on offspring testis and body weight, both in early and late development stages (19, 20). Interestingly, the offspring from ethanol-treated group showed faster weight gain and had significantly higher body weights on PN90 in

comparison to the controls. In addition, although there were no significant differences regarding the testis weight among the groups on PN90, relative (corrected for body weight) testis weights were not different among the groups from PN21 to PN90.

As mentioned above, several previous studies have examined long term effects of prenatal ethanol exposure on aspects of the testis and reproductive development. Prenatal ethanol exposure was shown to lower the serum level of testosterone and luteinizing hormones, reduce seminal vesicle weights, increase basal lamina touched genocytes, lower the testis weight, and lower the percentage of tubules with open lumina in offspring exposed to ethanol prenatally as well (19-21). The findings of this study are in contrast with some findings of previous studies such as testosterone level changes, LH surge changes and open lumina in prenatally ethanol exposed offspring. However, some studies have not shown any adverse effects caused by prenatal ethanol exposure on LH and testosterone levels in adulthood (22, 23). These contrary results from different studies indicate that further studies are needed to resolve these discrepancies in the literature.

The second issue addressed in this study was to find out whether maternal chronic ethanol consumption induces abnormality in offspring testis via oxidative stress. It was also intended to examine the effect of vitamin E to determine whether it inhibits the abnormality induced by ethanol in the testis of the offspring. The testis is more vulnerable to oxidative damage due to the presence of high levels of polyenoic fatty acids that are prone to oxidative decomposition. In addition, it is likely that the resultant lipid peroxidation contributes to the membrane injury and gonadal dysfunction that occur due to chronic ethanol use (24, 25). The desire to elucidate the mechanism by which ethanol exposure causes oxidative stress and free radicals production was the impetus for the study. In the ethanol-treated group, increased tissue Ox-LDL, the decreased total antioxidant capacity along with tissue damage were obviously caused by free radicals. Since lipid peroxidation is a self-propagation chain reaction, the initial oxidation of only a few molecules can result in significant tissue damage, especially in testis tissue which is rich in polyenoic fatty acids (24). Moreover, it was shown that maternal alcohol exposure caused an increase in protein carbonyl content of the testis tissue. Rajamani et al. reported that oxidative

modification of proteins causes structural alteration and functional inactivation of many enzymes (26). In the current study, it was found that ethanol exposure-related increases in protein carbonyl, Ox-LDL, and decreases in the antioxidant capacity, as well as testis tissue damage could be alleviated and restored to their normal status by vitamin E treatment.

Our previous studies and others have shown that vitamin E treatment prevents oxidative stress and tissue damage induced by ethanol consumption in the brain and testis (27, 28). Vitamin E exerts protective effects against ethanol-induced oxidative damage via its antioxidant properties as well as non-antioxidant dependent activities. As an antioxidant, vitamin E scavenges peroxy radicals and quenches other free radicals such as singlet O₂, superoxide and hydroxyl radicals. As previous studies have demonstrated, ethanol exposure increases the generation of hydrogen peroxide, superoxide and hydroxyl anions in cultured hepatocytes and neural crests (29, 30). Therefore, if alcohol exposure increases the production of free radicals and ROS *in vivo*, as has been demonstrated *in vitro*, vitamin E's protective effects may result from its ability to sequester these species, thereby preventing cellular damage. In addition to its ability to scavenge free radicals, vitamin E treatment can also influence the level of other endogenous antioxidants, perhaps contributing to its protective effects in tissue damaging.

Conclusion

Results of the current study provided evidence for the fact that maternal ethanol consumption induces histopathological and hormonal alterations in the testis of offspring in early and late postnatal days. At the structural level, it was revealed that with maternal chronic ethanol consumption during reproductive system development, alteration of the testis weight along with vacuolization of germ cells with glycogen droplet, low density of Leydig and Sertoli cells as well as more chromatin clumping in genocytes, were indicators of less activation and preparation of genocytes for mitosis in the offspring testis. In addition, the elevation of Ox-LDL and protein carbonyl amounts showed a more significant and stronger association between the ethanol induced changes in the structure of the testis via oxidative stress and a number of traditionally mentioned factors. Furthermore, addition of vitamin E to the diet ameliorated these alterations in the ethanol

group as compared to the control group. Further research is needed to elucidate the detailed mechanisms by which maternal ethanol consumption produces these testis defects in order to develop feasible prevention or treatment strategies for FASD.

Acknowledgement

This research was funded by the Office of the Vice Chancellor for Research and Technology, Urmia University of Medical Sciences.

Conflicts of Interest

All authors state that there are no actual or potential conflicts of interest including financial, personal, or other relationships with people or organizations within three years of beginning the submitted work that could inappropriately influence or be perceived to influence this work.

References

1. Barr HM, Streissguth AP. Identifying maternal self-reported alcohol use associated with fetal alcohol spectrum disorders. *Alcohol Clin Exp Res.* 2001;25(2):283-7.
2. Olson HC, Morse BA, Huffine C. Development and Psychopathology: Fetal Alcohol Syndrome and Related Conditions. *Semin Clin Neuropsychiatry.* 1998;3(4):262-84.
3. Roebuck TM, Mattson SN, Riley EP. A review of the neuroanatomical findings in children with fetal alcohol syndrome or prenatal exposure to alcohol. *Alcohol Clin Exp Res.* 1998;22(2):339-44.
4. Estrada G, Krasinski SD, Rings EH, Buller HA, Grand RJ, Lopez-Tejero MD. Prenatal ethanol exposure alters the expression of intestinal hydrolase mRNAs in newborn rats. *Alcohol Clin Exp Res.* 1996;20(9):1662-8.
5. Turcotte LA, Aberle NS, Norby FL, Wang GJ, Ren J. Influence of prenatal ethanol exposure on vascular contractile response in rat thoracic aorta. *Alcohol.* 2002;26(2):75-81.
6. Blanchard BA, Hannigan JH. Prenatal ethanol exposure: effects on androgen and nonandrogen dependent behaviors and on gonadal development in male rats. *Neurotoxicol Teratol.* 1994;16(1):31-9.
7. Dahlgren IL, Eriksson CJ, Gustafsson B, Harthorn C, Hard E, Larsson K. Effects of chronic and acute ethanol treatment during prenatal and early postnatal ages on testosterone levels and sexual behaviors in rats. *Pharmacol Biochem Behav.* 1989;33(4):867-73.
8. Hard E, Dahlgren IL, Engel J, Larsson K, Liljequist S, Lindh AS, Musi B. Development of sexual be-

- havior in prenatally ethanol-exposed rats. *Drug Alcohol Depend.* 1984;14(1):51-61.
9. Anderson RA Jr, Willis BR, Phillips JF, Oswald C, Zaneveld LJ. Delayed pubertal development of the male reproductive tract associated with chronic ethanol ingestion. *Biochem Pharmacol.* 1987;36(13):2157-67.
 10. Feroso J, Esquifino AI, Mateos A, Agrasal C, Martin I. Possible role of prolactin in the induction of hypogonadism by chronic alcohol treatment in the male rat. *Pharmacol Biochem Behav.* 1988;29(3):489-93.
 11. Bo WJ, Krueger WA, Rudeen PK, Symmes SK. Ethanol-induced alterations in the morphology and function of the rat ovary. *Anat Rec.* 1982;202(2):255-60.
 12. Lan N, Yamashita F, Halpert AG, Sliwowska JH, Viau V, Weinberg J. Effects of prenatal ethanol exposure on hypothalamic-pituitary-adrenal function across the estrous cycle. *Alcohol Clin Exp Res.* 2009;33(6):1075-88.
 13. Creighton-Taylor JA, Rudeen PK. Prenatal ethanol exposure and opiate influence on puberty in the female rat. *Alcohol.* 1991;8(3):187-91.
 14. Shirpoor A, Salami S, Khadem-Ansari MH, Minasian S, Yegiazarian M. Protective effect of vitamin E against ethanol-induced hyperhomocysteinemia, DNA damage, and atrophy in the developing male rat brain. *Alcohol Clin Exp Res.* 2009;33(7):1181-6.
 15. Kaartinen M, Penttilä A, Kovanen PT. Accumulation of activated mast cells in the shoulder region of human coronary atheroma, the predilection site of atheromatous rupture. *Circulation.* 1994;90(4):1669-78.
 16. Cybulsky MI, Won D, Haidari M. Leukocyte recruitment to atherosclerotic lesions. *Can J Cardiol.* 2004;20 Suppl B:24B-28B.
 17. Lan N, Yamashita F, Halpert AG, Ellis L, Yu WK, Viau V, et al. Prenatal ethanol exposure alters the effects of gonadectomy on hypothalamic-pituitary-adrenal activity in male rats. *J Neuroendocrinol.* 2006;18(9):672-84.
 18. Weinberg J, Kim CK, Yu W. Early handling can attenuate adverse effects of fetal ethanol exposure. *Alcohol.* 1995;12(4):317-27.
 19. Lan N, Vogl AW, Weinberg J. Prenatal ethanol exposure delays the onset of spermatogenesis in the rat. *Alcohol Clin Exp Res.* 2013;37(7):1074-81.
 20. Fakoya FA, Caxton-Martins EA. Morphological alterations in the seminiferous tubules of adult Wistar rats: the effects of prenatal ethanol exposure. *Folia Morphol (Warsz).* 2004;63(2):195-202.
 21. McGivern RF, Handa RJ, Raum WJ. Ethanol exposure during the last week of gestation in the rat: inhibition of the prenatal testosterone surge in males without long-term alterations in sex behavior. *Neurotoxicol Teratol.* 1998;20(4):483-90.
 22. Ward IL, Ward OB, French JA, Hendricks SE, Mehan D, Winn RJ. Prenatal alcohol and stress interact to attenuate ejaculatory behavior, but not serum testosterone or LH in adult male rats. *Behav Neurosci.* 1996;110(6):1469-77.
 23. Udani M, Parker S, Gavaler J, Van Thiel DH. Effects of in utero exposure to alcohol upon male rats. *Alcohol Clin Exp Res.* 1985;9(4):355-9.
 24. Aitken RJ, Clarkson JS, Fishel S. Generation of reactive oxygen species, lipid peroxidation, and human sperm function. *Biol Reprod.* 1989;41(1):183-97.
 25. Peltola V, Huhtaniemi I, Ahotupa M. Antioxidant enzyme activity in the maturing rat testis. *J Androl.* 1992;13(5):450-5.
 26. Rajamani R, Muthuvel A, Senthilvelan M, Sheela-devi R. Oxidative stress induced by methotrexate alone and in the presence of methanol in discrete regions of the rodent brain, retina and optic nerve. *Toxicol Lett.* 2006;165(3):265-73.
 27. Zhu Q, Emanuele MA, LaPaglia N, Kovacs EJ, Emanuele NV. Vitamin E prevents ethanol-induced inflammatory, hormonal, and cytotoxic changes in reproductive tissues. *Endocrine.* 2007;32(1):59-68.
 28. Taghizadeh Afshari A, Shirpoor A, Farshid A, Sadatian R, Rasmi Y, Saboory E, et al. The effect of ginger on diabetic nephropathy, plasma antioxidant capacity and lipid peroxidation in rats. *Food Chem.* 2007;101(1):148-53.
 29. Devi BG, Henderson GI, Frosto TA, Schenker S. Effect of ethanol on rat fetal hepatocytes: studies on cell replication, lipid peroxidation and glutathione. *Hepatology.* 1993;18(3):648-59.
 30. Davis WL, Crawford LA, Cooper OJ, Farmer GR, Thomas DL, Freeman BL. Ethanol induces the generation of reactive free radicals by neural crest cells in vitro. *J Craniofac Genet Dev Biol.* 1990;10(3):277-93.