

Primary Tuberculosis of Cervix: A Coincidental Finding

Nalini Sharma ^{1*}, Ahanthem Santa Singh ¹, Yookarin Khonglah ², Jaya Mishra ²

1- Department of Obstetrics and Gynaecology, North Eastern Indira, Gandhi Regional Institute of Health and Medical Sciences, Shillong, Meghalaya, India

2- Department of Pathology, North Eastern Indira, Gandhi Regional Institute of Health and Medical Sciences, Shillong, Meghalaya, India

Abstract

Background: 95% of Tuberculosis (TB) of the female genital tract (FGT) is located in tissues other than the cervix. A rare case of primary TB of the cervix which was diagnosed coincidentally in a patient of endometrioma was reported in this study.

Case Presentation: A 34 year old nullipara, a diagnosed case of endometrioma had a small cervical growth. Pap smear and biopsy was taken and sent for histopathological examination. Her histopathological examination revealed multiple epitheloid cell granuloma and langerhans type giant cell caeseation. Ziehl neelsen staining was positive for acid fast bacilli (AFB). The patient was started on antituberculosis under directly observed therapy along with oral contraceptive pills. Patient was on regular follow-up and clinically she was doing well.

Conclusion: Although cervical tuberculosis is very rare but for an abnormal looking cervix, cervical tuberculosis should be considered in the differential diagnosis in woman of all the age groups especially in areas where tuberculosis is rampant since these cases are potentially curable with medical therapy. Many of these patients are in reproductive age group. In young women, early diagnosis prevents further damage in reproductive tract and can improve their reproductive potential.

Keywords: Cervix, Genital tuberculosis, Tuberculosis.

To cite this article: Sharma N, Singh AS, Khongah Y, Mishra J. Primary Tuberculosis of Cervix: A Coincidental Finding. *J Reprod Infertil.* 2016;17(4):247-249.

* Corresponding Author:

Nalini Sharma, North Eastern Indira, Gandhi Regional Institute of Health and Medical Sciences Shillong, Meghalaya, India

E-mail:

Srmsims_sharma@rediffmail.com

Received: 15, Sept. 2015

Accepted: 22, Dec. 2015

Introduction

Genital TB is still a major socioeconomic burden in resource poor settings. 95% of TB of the female genital tract (FGT) is located in tissues other than the cervix. A rare case of primary TB of the cervix which was diagnosed coincidentally in a patient with endometrioma was reported in this study.

Case Presentation

A 34 year old unmarried, nulligravida presented (somewhere July-August 2014) to gynecology OPD in North Eastern Indira, Gandhi Regional Institute of Health and Medical Sciences, Shillong, Meghalaya with chief complaint of pain in lower abdomen for 5-6 years. She was operated for endometrioma twice. Her first surgery was laparoscopic cystectomy for right ovarian endometrioma 4 years ago. Her second surgery was

open cystectomy for left ovarian endometrioma 2 years ago. Patient had the history of sexual contact. Her general physical examination was normal. In her first visit, in speculum examination, cervix and vagina were healthy. In bimanual examination, her uterus was normal size, retroverted, right fornix was tender and an ill defined mass about 5 cm was present with restricted mobility. Left fornix was clear. In ultrasonographic examination, 6 by 5 cm endometrioma was present in right ovary. As the patient was not willing for further surgery and fertility was not an issue, she was put on continuous oral contraceptive pill with three monthly regimens. She responded very well on treatment. Her pain and dysmenorrhoea were relieved. Her endometrioma decreased in size by 4 by 3 cm in repeat ultrasonographic examination after nine months of therapy. As she was on oral

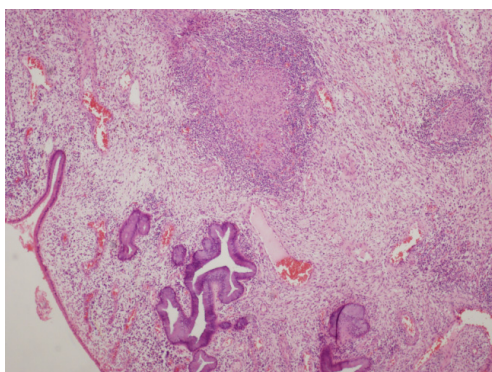


Figure 1. H&E, 4X-Section showing endocervical epithelium with epitheloid granuloma in the stroma

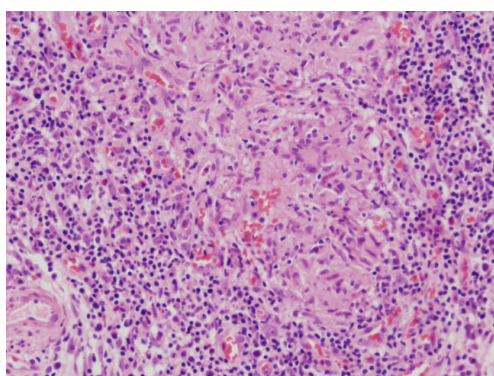


Figure 2. H&E, 20x Epitheloid granuloma with langerhans giant cells

contraceptive pill, pap smear was advised. This time about after nine months (on 6th April 2015) in speculum examination, a small growth about 0.5 cm, pink, smooth, firm, non-forcible and non bleeding on touch, a cervical polyp was present on anterior lip of cervix. Pap smear and biopsy was taken and sent for histopathological examination. Pap smear was inflammatory, negative for dysplasia and malignancy. Her histopathological examination revealed multiple epitheloid cell granulomas and langerhans type giant cell caeseation. Ziel neelsen staining was positive for acid fast bacilli. In retrospective interrogation, she denied any history of chronic cough, loss of weight or fever. She did not have menstrual irregularity, post coital bleeding, discharge per vaginum, any bowel or bladder complaint. There was no history of personal or family exposure to tuberculosis. Her chest X-ray was normal. Her urine and sputum sample were negative for AFB. Antibody test for HIV was negative. On the basis of histopathological examination and AFB staining report, diagnosis of cervical tuberculosis was established (Figures 1 and 2). The patient was started on anti-

tubercular drugs under directly observed therapy along with oral contraceptive pills. Patient was on regular follow-up. She was asymptomatic before diagnosis and treatment of cervical tuberculosis and her growth was already removed during biopsy. On follow-up, her cervix was normal.

Discussion

Endometriosis and cervical tuberculosis have no common risk factors except that both are seen in reproductive age group and both can lead to infertility, although in the present case, infertility was not an issue. Here, cervical tuberculosis was just a coincidental finding. Although pulmonary tuberculosis is the most common form, genitourinary TB is also common in developing countries. It usually involves fallopian tube (95-100%), endometrium (50-60%) and ovary (20-30%). TB of cervix is extremely rare and accounts for 0.1-0.65% of all cases of TB and 5-24% of genital tract TB (1-5). Genital involvement is usually secondary to extra genital TB which in most cases arises from pulmonary focus (2, 4, 5). Spread of infection to the cervix is either by hematogenous or lymphatic route or by direct local extension from tubercular salpingitis or endometritis (2, 4, 5). Rarely cervical involvement may occur via sexual contact with a partner who is affected by genitourinary TB (1, 2, 4-6). It has been suggested that sputum used as sexual lubricant may also be a route of transmission (4, 6). In extremely rare cases, primary cervical tuberculosis may occur if a person sits on infected sputum. In the present case, there is no personal history of TB and her partner also didn't have any obvious urogenital manifestation. Many patients remain asymptomatic as in our case. Genital tract TB usually presents with abnormal vaginal bleeding or discharge, menstrual irregularities, abdominal pain, infertility, postmenopausal bleeding and other constitutional symptoms (1-9). In clinical presentation, it may be papillary, endophytic, exophytic, ulcerative growth which may simulate cervical cancer (2-5). In the present case, patient did not have symptoms pertaining to cervical pathology. The diagnosis of cervical TB is often established by histopathological examination of cervical biopsy specimen (2, 4, 7) and sometimes by staining for AFB as happened in the present case. AFB may not be always provable in cytological smear (10). Although culture of mycobacterium is considered the gold standard for diagnosis, but in 30% of cases, the culture may be negative (2-5, 7, 10).

Therefore, presence of typical granuloma is enough for diagnosis (2-5, 7, 10). Cervical TB usually responds to six months of standard anti-tuberculosis therapy.

Conclusion

Although cervical tuberculosis is very rare but for an abnormal looking cervix, cervical tuberculosis should be considered in the differential diagnosis in woman of all age groups especially in areas where tuberculosis is rampant since these cases are potentially curable with medical therapy. Many of these patients are in reproductive age group. In young women, early diagnosis prevents further damage in reproductive tract and can improve their reproductive potential.

Conflict of Interest

Authors declare no conflict of interest.

References

1. Agarwal J, Gupta JK. Female genital tuberculosis--a retrospective clinico-pathologic study of 501 cases. *Indian J Pathol Microbiol.* 1993;36(4):389-97.
2. Lamba H, Byrne M, Goldin R, Jenkins C. Tuberculosis of the cervix: case presentation and a review of the literature. *Sex Transm Infect.* 2002;78(1):62-3.
3. Elkattan E, Abdeibadei M, Hettow H, Hussein E, As-saad J. Tuberculosis cervicitis mimicking cancer cervix: A case study. *Middle East Fertil Soc J.* 2014;19(1):75-7.
4. Barmon D, Kataki AC, Sharma JD, Gharpholia D. A case of cervical tuberculosis mimicking cervical carcinoma. *J Obstet Gynaecol India.* 2013;63(4):285-7.
5. Ahmed S, Oguntayo A, Odogwu K, Abdullahi K. Tuberculous cervicitis: A case report. *Niger Med J.* 2011;52(1):64-5.
6. Chowdhury NN. Overview of tuberculosis of the female genital tract. *J Indian Med Assoc.* 1996;94(9):345-6, 361.
7. Paprikar M, Biswas M, Bhattacharyav S, Sodih B, Mukhopadhyay I. Tuberculosis of cervix. *Med J Armed Forces India.* 2008;64(4):297-8.
8. Mukerji S, Moncur L, Sanders B, Currie A, Watson A, Leeman K. Difficulties in diagnosing tuberculosis of the cervix in a post menopausal woman: Case report and literature review. *Australas Med J.* 2013;6(7):367-70.
9. Joshi PS, Shankar V, Sinha P. An unusual case of cervical tuberculosis. *Online J Health Allied Scs.* 2011;10(1):1-2.
10. Seth A, Kudesia M, Gupta K, Pant L, Mathur A. Cytodiagnosis and pitfalls of genital tuberculosis: A report of two cases. *J Cytol.* 2011;28(3):141-3.