



Successful Management of Caesarean Scar Ectopic Pregnancies: A Report of Five Cases

Neena Malhotra¹, Nilofar Noor¹, Piyush Bansal², K. Aparna Sharma^{1*}

1- Department of Obstetrics and Gynaecology, All India Institute of Medical Sciences, New Delhi, India

2- Department of Obstetrics and Gynaecology, All India Institute of Medical Sciences, Nagpur, India

Abstract

Background: Cesarean section scar ectopic pregnancy (CSEP) is a rare and potentially life-threatening condition. A standardized management protocol is yet to be established owing to limited data available.

Case Presentation: In this paper, five cases of CSEP over a period of 18 months at a tertiary referral hospital, managed medically with methotrexate administered both systemically and into the gestational sac at the time of feticide with potassium chloride (KCL) are presented. Surgical management was the second line therapy when medical treatment failed.

Conclusion: With rising trends in cesarean deliveries, CSEP may be a challenge which requires close investigation regarding its diagnosis and treatment on the merits of case studies and available healthcare facilities.

Keywords: Cesarean section, Ectopic pregnancy, Gestational sac, Methotrexate.

To cite this article: Malhotra N, Noor N, Bansal P, Sharma KA. Successful Management of Caesarean Scar Ectopic Pregnancies: A Report of Five Cases. *J Reprod Infertil.* 2021;22(3):220-224. <http://dx.doi.org/10.18502/jri.v22i3.6723>.

* Corresponding Author:

K. Aparna Sharma,
Department of Obstetrics
and Gynecology, All India
Institute of Medical
Sciences, New Delhi-
110029, India
E-mail:
kaparnasharma@gmail.com

Received: May 14, 2020

Accepted: Sept. 17, 2020

Introduction

Caesarean scar ectopic pregnancy (CSEP) is complete or partial implantation within the myometrial defect of previous uterine scar (1). Two types of the problem have been described (2) as endophytic mass which grows towards the endometrial cavity and may result in viable ongoing pregnancy, with high risk of morbidly adherent placenta and major obstetric haemorrhage and exophytic one that grows into the myometrium, towards the serosa with complications like uterine rupture and haemorrhage in the first trimester (1).

Diagnosis is primarily by ultrasound, supported by MRI when in doubt. The diagnostic ultrasound criteria include (1) empty uterine cavity and endocervical canal, (2) gestational sac embedded in previous scar at the level of internal os, (3) thin or absent layer of myometrium between the gestational sac and bladder, (4) increased vascularity seen on Doppler, and (5) negative 'sliding organ

sign' while applying pressure by endovaginal probe and no displacement of gestational sac from its position at the level of the internal os (1).

Owing to the rarity of cases of CSEP, there is lack of consensus on the best treatment modality, and both medical and surgical management have shown good outcome. Medical management with methotrexate (Systemic or combined local and systemic) has been adopted as the first line therapy in our center provided that the following criteria are met: (a) haemodynamic stability; (b) asymptomatic or mild symptoms; (c) intact scar on imaging; and (d) willingness for medical therapy, follow up and emergency surgical interventions if needed.

All patients were kept under close follow up and requisite preparations were made for surgical intervention if deemed necessary. The outcome of CSEP which was managed medically at our center is reviewed in this paper.

Case Presentation

Case records of five women diagnosed with CSEP and managed over a period of 18 months from December, 2017 to May, 2019 at a tertiary referral hospital were reviewed. In those with a live ectopic pregnancy, feticide was achieved with intracardiac instillation of potassium chloride (KCL) under transvaginal ultrasound (TVS) guidance using a 17-gauge double-lumen ovum aspiration needle, followed by local methotrexate (Half of the calculated dose equal to 50 mg/m^2) injected into the gestational sac (Figure 1). The remaining dose was given intramuscularly. Serum human chorionic gonadotropin (hCG) levels were measured on day 1, 4 and 7, and a fall of 15% between day 4 and 7 was considered adequate. If this fall was not seen, then additional dose of intramuscular methotrexate was injected (50 mg/m^2). Systemic multiple dose regimen was given in one case which consisted of intravenous methotrexate 1 mg/kg for four doses (Day 1, 3, 5, 7) alternating with intravenous leucovorin 0.1 mg/kg (Day 2, 4, 6, 8). Serial hCG monitoring of the five cases at our center is depicted in figure 2. Those not responding to medical therapy were managed surgically. Written permission for reporting the cases was obtained from the patients.

The first case, a 24 year old, G2P1L1, with previous caesarean section (CS), was referred after failed dilatation and curettage treatment due to profuse bleeding and was controlled with intracervical Foley's balloon catheter inserted in the cervix. Ultrasound revealed a live 9-week endophytic scar ectopic pregnancy. Local and systemic methotrexate were given and hCG levels returned to normal in 8 weeks (Figure 2).

The second case, a 32 year old, G3P2L2, with two previous CS received oral mifepristone and misoprostol for pregnancy termination which failed and subsequently was consulted on persistent-

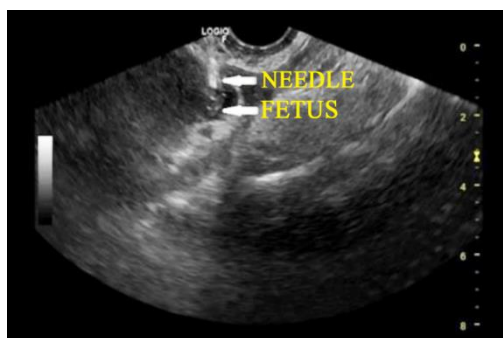


Figure 1. Transvaginal ultrasound guided intrafetal injection of KCL and methotrexate instillation

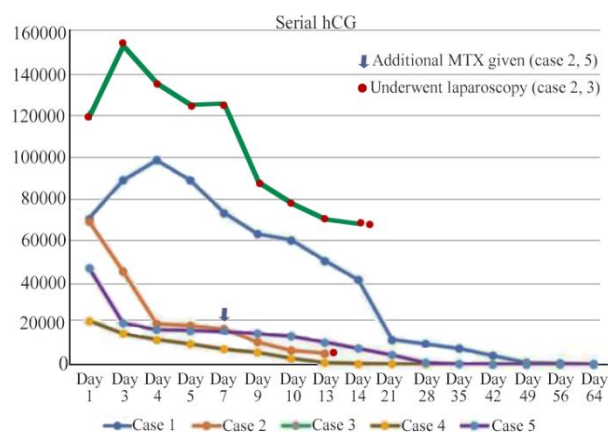


Figure 2. Serial hCG trends in the 5 cases. Day 1 was the day of local/systemic methotrexate therapy at our center

↓ Indicates additional methotrexate doses

* Indicates laparoscopic intervention

mild vaginal bleeding. Ultrasound revealed a live 11-week scar ectopic pregnancy with increased vascularity in the anterior uterine wall on Doppler. MRI confirmed an exophytic variant with thinning of anterior myometrium ($<2 \text{ mm}$) (Figure 3). Serum hCG level was 67.574 IU/L . Feticide with intra-sac KCL was achieved followed by giving combined local and systemic methotrexate at a dose of 50 mg/m^2 . Serum hCG levels were monitored and an additional dose of intramuscular methotrexate was given (50 mg/m^2) as the fall between day 4 and 7 was less than 15%. Subsequently, $>70\%$ decline in hCG levels from the baseline value was achieved as depicted in figure 2, prompting the staff to begin discharge activities. However, she had been readmitted 2 days later with acute abdominal pain and was managed surgically. Hysteroscopy (Showing an empty uterine cavity) was followed by laparoscopic excision of caesarean scar ectopic pregnancy. Dilute vasopressin was infiltrated into scar for hemostasis, bladder was separated from the lower uterine segment carefully, and sac was enucleated after incision was made over the thinned myometrium.

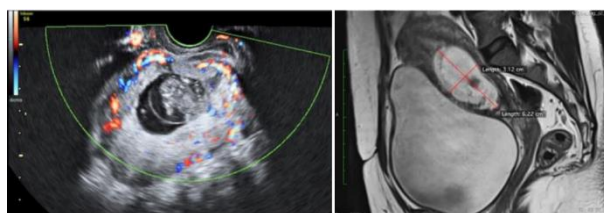


Figure 3. Color Doppler showing increased vascularity and MRI film showing anterior myometrial thickness $<2 \text{ mm}$

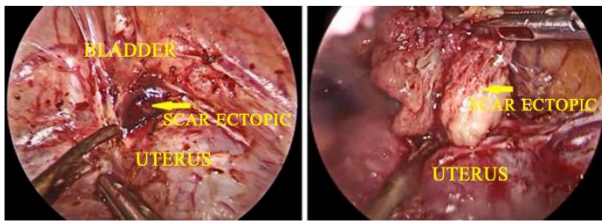


Figure 4. Laparoscopic excision of caesarean scar ectopic pregnancy

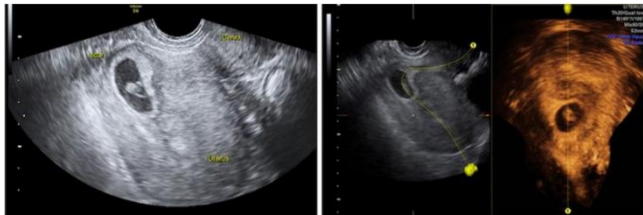

Figure 5. 2D and 3D USG view of the CSEP

The incision was freshened and repaired with barbed sutures (Figure 4).

In the third case, a 33 year old, G4P1L1A2, who had a prior CS, 2D ultrasound suggested a live 8-week scar ectopic pregnancy. A 3D USG confirmed its endophytic type (Figure 5). With hCG levels of 117.048 IU/L, intra-sac KCL for feticide and intravenous methotrexate 1 mg/kg was given at four doses (Day 1, 3, 5, 7) alternating with intravenous leucovorin 0.1 mg/kg (Day 2, 4, 6, 8). Following this procedure, >15% fall was noted between day 4 and 7 and she did not require further methotrexate doses (Figure 2). However, despite good response, the patient opted for surgery after two weeks to shorten the follow up. Laparoscopic excision of scar followed by repair was done (Figure 6).

The fourth case, a 40 year old third gravida with two previous CS, was diagnosed with endophytic

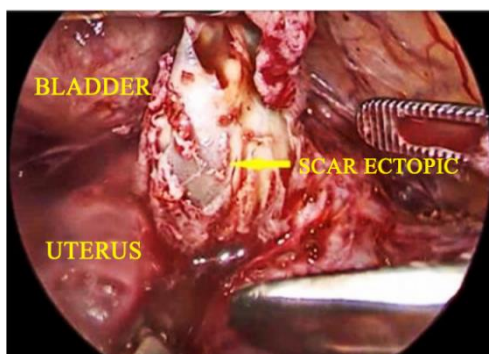


Figure 6. Laparoscopic excision of 3cm caesarean scar ectopic mass

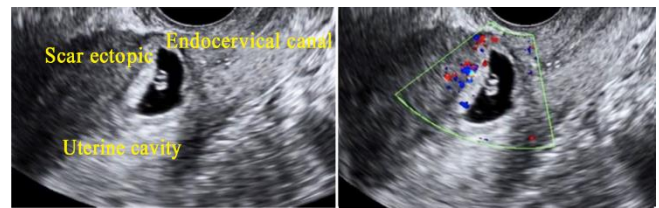


Figure 7. Ultrasound showing empty uterine cavity and endocervical canal. Ectopic pregnancy seen at the level of previous caesarean scar. Doppler study shows increased vascularity

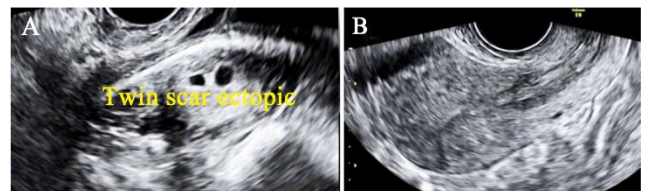


Figure 8. A) Twin scar ectopic pregnancy. B) Complete resolution of scar ectopic mass on follow up scan

type of CSEP and crown rump length (CRL) was measured to be 6 weeks of gestation (Figure 7). She had already received two doses of systemic methotrexate in a local clinic, but hCG had failed to show a significant decline from initial level of 21000 IU/L. She was treated with TVS guided intra-sac methotrexate which achieved a good response with hCG levels normalized in 6 weeks. The trend of her serum hCG decline following intra-sac methotrexate is depicted in figure 2.

The fifth case, a 34 year old, with one previous CS was diagnosed with 8-week endophytic CSEP on ultrasound and two gestational sacs (Figure 8A). She received oral misoprostol at another clinic and experienced heavy bleeding for 3 days and self-referred to our center where ultrasound confirmed CSEP. Following adequate blood replacement, two doses of systemic methotrexate achieved complete response and resolution of ectopic mass by 9 weeks on ultrasound (Figure 8B).

Discussion

CSEP is a rare but life-threatening complication with incidence of 1 in 2000 pregnancies (1). First reported in 1978 by Larsen et al. (3), there has been an increasing trend with rise in caesarean deliveries and improved diagnostic modalities (4). Previous caesarean for breech presentation has been linked with increased risk, likely due to poorly formed lower uterine segment and higher uterine incision (4) but this was not seen in our

series. Studies have not shown multiple uterine surgeries as an independent risk factor (5).

Clinical presentation of CSEP is variable with vaginal bleeding and pain being common presentations. Four out of the five women in our series were asymptomatic, while one presented with vaginal bleeding. In a systemic review by Gonzalez and Tulandi (6), vaginal bleeding was the most common symptom while a third of patients were asymptomatic.

Management remains unclear and all recommended methods do not have an edge over the others (1). Treatment needs to be individualized based on symptomatology, haemodynamic status, serum hCG levels, imaging features, and surgeon's expertise (6). Expectant management is rarely adopted and reserved for woman refusing termination, having endophytic type of CSEP and a small sac with no cardiac activity or pregnancy likely to fail (7).

Medical management has the advantage of being noninvasive, but patients need thorough counselling regarding the risk of haemorrhage, long term follow up with serial hCG measurements, and possibility of surgical intervention including hysterectomy (1, 4). Methotrexate is the drug of choice. Most researchers suggest single dose methotrexate regimen and follow up, with 50 mg/m² dose given and repeated weekly if needed (4) based on the response to serum hCG. Systemic methotrexate alone is most effective when hCG levels are <5000 IU/L, gestational age is less than 8 weeks with absent fetal cardiac activity, and the mass is less than 3 cm on USG (1, 4, 6). However, in our series, serum hCG levels ranged from 21000 to 120000 IU/L at gestational age of 6 to 11 weeks, and fetal cardiac activity was present in 3 cases. Therefore, a combination of local and systemic methotrexate was selected which gives a better success rate (4, 8). Local methotrexate using transvaginal ultrasound offers the advantage of being anatomically closer to target site allowing greater ease and less visceral injuries (4, 8). Sadeghi et al. (9) reported a review of 19 cases, where a combination of local and systemic methotrexate was successful in 74% of women. However, several researchers advocate local methotrexate as the first line treatment (1, 6, 10) because fibrosis at the previous scar may limit exposure of systemic methotrexate to trophoblast (6). Even in our series, it can be noted that the fourth case failed to show response to systemic methotrexate but local therapy was successful. Fetal intracardi-

ac instillation of KCL, when combined with local or systemic methotrexate, achieves faster resolution (4, 11) and reduces risk of haemorrhage (12). Multiple dose regimen was used in one patient where the hCG levels were greater than 100000 IU/L with the aim to achieve more effective and rapid response. Gupta et al. (11) reported a case of live scar ectopic pregnancy with hCG levels of 297969 mIU. Four doses of 1 mg/kg intravenous methotrexate alternating with leucovorin, along with intra-sac KCL and methotrexate injection achieved a successful outcome, though hCG took 119 days to normalize. Another case of live CSEP was managed successfully with five doses of methotrexate alternating with leucovorin (13).

Surgical management facilitates complete removal of conceptus, faster recovery, shorter follow-up due to rapid normalization of hCG levels (6, 14). Dilation and curettage (D&C) or hysteroscopic resection are alternative approaches for management of endophytic type of CSEP. These may be combined with additional hemostatic measures (1, 4, 14).

Excision techniques are suitable for exophytic type of CSEP (1, 4, 6). Two patients in our series had laparoscopic excision with scar repair, one was on patient's request while the other, exophytic variant, was performed due to failed medical management. Some researchers advocate uterine artery embolization (UAE) prior to surgery for better haemostasis (4). However, both of our cases had already received medical treatment which is known to reduce vascularity (4). Since laparoscopic uterine artery ligation could be performed professionally if needed, UAE as additional procedure was avoided. It is not proven that scar repair reduces risk of recurrence (1).

All cases need to be followed until normalization of serum hCG and advised to undergo an early ultrasound in subsequent pregnancies to rule out recurrence, the possibility of morbidly adherent placentation, and uterine rupture. Recurrence rate varies from 5% to 15% (15, 16) and risk factors include myometrial thickness <5 mm, CS in a rural setup, history of irregular vaginal bleeding, and pain during previous CSEP (4, 5).

Conclusion

With rising trend in cesarean deliveries, an increase in CSEPs is anticipated. The ability to diagnose and treat this condition is vital for practicing clinicians. Medical and surgical approaches have a successful outcome and individualized

management tailored to patient's needs and surgeon's expertise is essential. Medical management has the advantage of being noninvasive and therefore can be adopted as the first line therapy for eligible patients in centers with round the clock requisite facilities for close follow up and emergency surgical intervention.

Conflict of Interest

None.

References

1. No authors listed. Diagnosis and management of ectopic pregnancy: Green-top Guideline No. 21. *BJOG*. 2016;123(13):e15-55.
2. Vial Y, Petignat P, Hohlfeld P. Pregnancy in a cesarean scar. *Ultrasound. Obstet Gynecol*. 2000;16(6):592-3.
3. Larsen JV, Solomon MH. Pregnancy in a uterine scar sacculus--an unusual cause of postabortal haemorrhage. A case report. *South Afr Med J Suid-Afr Tydskr Vir Geneeskde*. 1978;53(4):142-3.
4. Jayaram PM, Okunoye GO, Konje J. Cesarean scar ectopic pregnancy: diagnostic challenges and management options. *Obstet Gynaecol*. 2017;19(1):13-20.
5. Qian ZD, Guo QY, Huang LL. Identifying risk factors for recurrent cesarean scar pregnancy: a case-control study. *Fertil Steril*. 2014;102(1):129-34.e1.
6. Gonzalez N, Tulandi T. Cesarean scar pregnancy: a systematic review. *J Minim Invasive Gynecol*. 2017;24(5):731-8.
7. Jayaram P, Okunoye G, Al Ibrahim AA, Ghani R, Kalache K. Expectant management of caesarean scar ectopic pregnancy: a systematic review. *J Perinat Med*. 2018;46(4):365-72.
8. Seow KM, Wang PH, Huang LW, Hwang JL. Transvaginal sono-guided aspiration of gestational sac concurrent with a local methotrexate injection for the treatment of unruptured cesarean scar pregnancy. *Arch Gynecol Obstet*. 2013;288(2):361-6.
9. Sadeghi H, Rutherford T, Rackow BW, Campbell KH, Duzyj CM, Guess MK, et al. Cesarean scar ectopic pregnancy: case series and review of the literature. *Am J Perinatol*. 2010;27(2):111-20.
10. Cheung VYT. Local Methotrexate injection as the first-line treatment for cesarean scar pregnancy: review of the literature. *J Minim Invasive Gynecol*. 2015;22(5):753-8.
11. Gupta M, Kriplani A, Mahey R, Kriplani I. Successful management of caesarean scar live ectopic pregnancies with local KCL and systemic methotrexate. *BMJ Case Rep*. 2017;2017:bcr 2017221844.
12. Kaur R, Goel B, Sehgal A, Goyal P, Mehra R. Feticide with intracardiac potassium chloride to reduce risk of hemorrhage in medical termination of pregnancy. *J Gynecol Women Healthc*. 2018;1(1):1-4.
13. Roy MM, Radfar F. Management of a viable cesarean scar pregnancy: a case report. *Oman Med J*. 2017;32(2):161-6.
14. Deans R, Abbott J. Hysteroscopic management of cesarean scar ectopic pregnancy. *Fertil Steril*. 2010;93(6):1735-40.
15. Ben Nagi J, Helmy S, Ofili-Yebovi D, Yazbek J, Sawyer E, Jurkovic D. Reproductive outcomes of women with a previous history of caesarean scar ectopic pregnancies. *Hum Reprod*. 2007;22(7):2012-5.
16. Wang Q, Peng HL, He L, Zhao X. Reproductive outcomes after previous cesarean scar pregnancy: Follow up of 189 women. *Taiwan J Obstet Gynecol*. 2015;54(5):551-3.