



## Mixed Gonadal Dysgenesis with 45,X/46,X,idic(Y)/46,XY Karyotype: A Case Report

Reshma Ammu Shetty<sup>1</sup>, Deyyanthody Prashanth Shetty<sup>1\*</sup>, Pooja Swaroop Kulshreshtha<sup>2</sup>, Jayarama Shanker Kadandale<sup>2</sup>

1- KSHEMA Center for Genetic Services, K.S. Hegde Medical Academy, Nitte University, Karnataka, India

2- Center for Human Genetics, Karnataka, India

### Abstract

**Background:** The purpose of the current study was to report a case with 45,X/46,XY/46,X,idic(Yp) mosaicism showing the male phenotype with mixed gonadal dysgenesis.

**Case Presentation:** A 27 year-old individual, phenotypically male, presented with azoospermia and a micropenis. Both testes were not visualized in the scrotal sac. Due to the presence of a small-sized uterus, the individual was referred to the KSHEMA Center for Genetic Services for chromosomal analysis. Karyotyping revealed a mosaic karyotype of 45,X[44]/46,XY[5]/46,X,idic(Yp)[1]. This finding was further confirmed through fluorescent in situ hybridization (FISH) analysis. The individual's mosaic karyotype consisted of three cell lines, with a higher proportion of the 45,X cell line and lower proportions of the idic(Yp) and 46,XY cell lines. It is worth noting that this mosaic condition in postnatal peripheral blood has not been reported in the literature thus far.

**Conclusion:** The case report demonstrated the importance of performing karyotype and FISH analysis in understanding genetic defects including mosaicism and other chromosomal aberrations, which can influence not only growth and puberty but also sexual development and maturation. Hence, performing cytogenetic and molecular cytogenetic analysis will help clinicians to take a further step in understanding and managing the condition.

**Keywords:** Azoospermia, Fluorescent in situ hybridization (FISH), Isodicentric Y, Karyotyping, Mosaicism.

**To cite this article:** Shetty RA, Shetty DP, Kulshreshtha PS, Kadandale JS. Mixed Gonadal Dysgenesis with 45,X/46,X,idic(Y)/46,XY Karyotype: A Case Report. *J Reprod Infertil.* 2024;25(1):72-76. <https://doi.org/10.18502/jri.v25i1.15203>.

\* Corresponding Author:  
Deyyanthody Prashanth Shetty, KSHEMA Center for Genetic Services, K.S. Hegde Medical Academy, Nitte University, Karnataka, India  
E-mail:  
dprashanthshetty@gmail.com,  
drprashanth@nitte.edu.in

Received: 30, May 2023

Accepted: 25, Oct. 2023

### Introduction

Abnormalities involving sex chromosomes account for approximately 0.5% of live births and the phenotypes of individuals with mosaic cell lines having structural aberrations of the X and Y chromosomes are variable. True hermaphroditism is one of the rarest genetic disorders of sexual differentiation, found in approximately 5% of all such cases. Genotype 45,X/46,XY mosaicism refers to the presence of two different cell lines within an individual (1). This genotype shows a broad spectrum of phenotypic

features, ranging from females with or without Turner-like stigmata, to males and females with gonadal dysgenesis and to phenotypically normal males (2). This also refers to mosaic males with structural abnormal Y chromosome (3). Sex differentiation can be challenging in individuals with 45,X/46,XY mosaicism. The occurrence of these mosaics is estimated to be around 1.5 to 1.7 per 10,000 individuals (4, 5).

The isodicentric Y chromosome [idic(Y)] is one of the most common structural abnormalities of

the Y chromosome. It was recorded first by Jacobs and Ross (6) and is most commonly observed in the structural chromosomal aberrations of the Y chromosome (7). It is believed that the development of idic(Y) chromosomes occurs after the Y chromosomal break which results from recombination within the chromosome or fusion between sister chromatids (8). The positions of the breakage and fusion of the Y chromosome significantly differ (9). The breakpoint of the idic(Y) chromosome plays a crucial role in determining the preserved Y content, leading to highly variable Y chromosome duplications and deletions. Owing to the presence of two centromeres, idic(Y) chromosomes exhibit a certain degree of instability, resulting in the formation of multiple mosaicism (10).

### Case Presentation

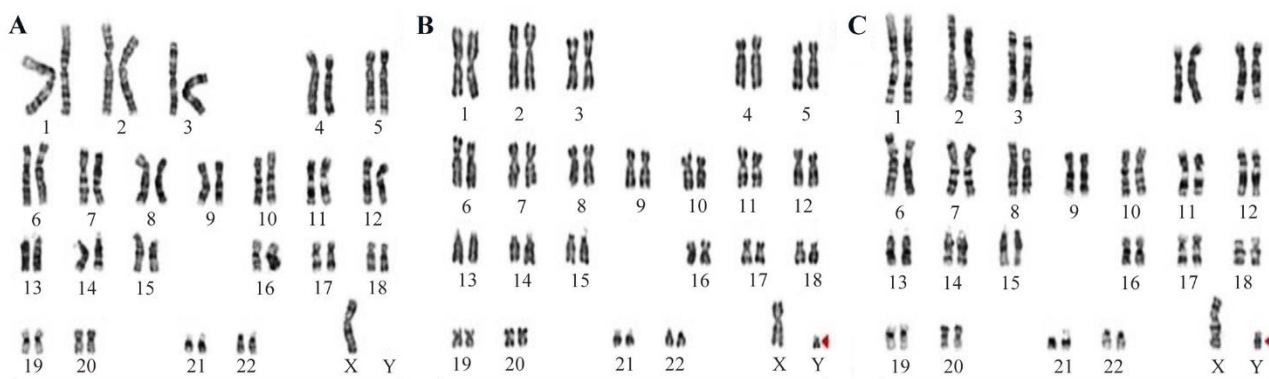
A 27 year-old man (5.2 feet) was referred to the KSHEMA Centre for Genetic Services for karyotyping from Urology Department at Yenepoya Hospital in 2021. He was phenotypically male. A T-MRI scan of the pelvis revealed the presence of a micropenis and a bifid scrotum with a midline cleft in the scrotum. However, both testes were not observed within the scrotal sac. A unicornuate uterus with an anteverted position and reduced size was observed. Elongated tubular cystic structure with incomplete septations was indicated in left iliac fossa, indicating a possible diagnosis of hydrosalpinx. A well-defined solid lesion was observed in the right iliac fossa, which could potentially indicate the presence of an ovotestis. These features are suggestive of true hermaphroditism. Sperm analysis showed azoospermia. Fluorescence in situ hybridization (FISH) investiga-

tion and chromosomal analysis were carried out in the genetic laboratory of K.S. Hegde Medical Academy, Karnataka, India. T-MRI scan and sperm analysis were performed at Yenepoya Hospital, Karnataka, India, during October 2021.

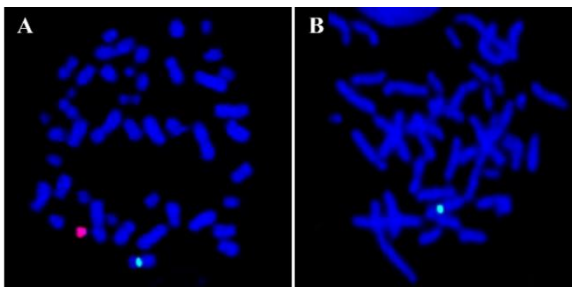
**Chromosomal analysis:** GTG banding was performed on the cultured peripheral blood sample and a total of 50 well-spread metaphases were captured using Olympus BX53 microscope. The metaphases were analyzed using GenASIs software version 8.1. The analysis revealed the following karyotype: 45,X[44]/46,XY[5]/46,X,idic(Yp)[1]. All three karyotypes are shown in figure 1 which confirms a mosaic karyotype, with 88% of cells exhibiting monosomy for the X chromosome, 2% of cells showing an idic(Yp) chromosome, and 10% of cells being normal. The karyotypes were reported according to the International System for Human Cytogenomic Nomenclature 2016 (ISCN 2016).

**Fluorescence in situ hybridization (FISH) analysis:** FISH was done on the cultured peripheral sample using the standard protocol (11) with slight modification. The FAST FISH prenatal enumeration probe kit (Cytocell, UK) was utilized, targeting the Xp11.1-q11.1 region (DXZ1 green) and Yp11.1-q11.1 region (DYZ3 orange) on interphase nuclei and metaphases obtained from peripheral blood sample (Figure 2).

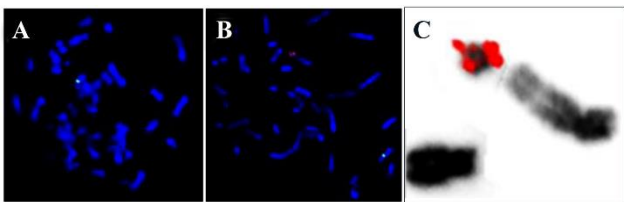
The FISH analysis utilized two different probes. The first probe, LSI SRY (red)/CEPX (green) (Cytocell, UK) was localized to Yp11.3 and p11.1-q11.1 regions of the X chromosome (Figure 3). The second probe, SE X (DXZ1-red)/SE Y (DYZ1-green) (Kreatech<sup>TM</sup>, Netherlands), was localized to the p11.1-q11.1 region of the X chromosome and q12 region of the Y chromosome



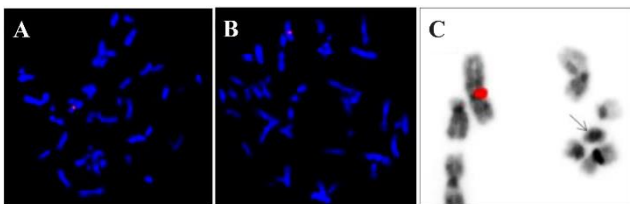
**Figure 1.** Male karyotype analysis showing the distribution of cell lines observed in a total of 50 cells. Cell line A exhibits 45,X in 44 cells, cell line B shows 46,XY in 5 cells, and cell line C displays 46,X,idic(Yp) in 1 cell



**Figure 2.** A) Metaphase showing one green signal for X chromosome and one red signal for Y chromosome, B) Metaphase showing one green signal for chromosome X



**Figure 3.** LSI SRY(red)/CEPX(green); A) 45,X cell line with only one green signal for X chromosome; B) 46,X, idic(Yp) cell line with one green signal for X chromosome and two red signals for SRY on the abnormal Y chromosome; C) inverted DAPI image showing two signals for SRY on idic(Yp)



**Figure 4.** SE X (DXZ1-red)/SE Y (DYZ1-green); A) 45,X cell line with only one red signal for X chromosome; B) 46,X, idic(Yp) cell line with one red signal for X chromosome and no green signals for Yq12 heterochromatin region on the abnormal Y chromosome; C) inverted DAPI image showing suspected idic(Yp) without any signals for Yq12 heterochromatin

(Figure 4). FISH images were visualized and captured using Axio Imager Z2 upright fluorescence microscope (Carl Zeiss, Germany) and analyzed using Isis software (MetaSystems, Germany).

The abnormal Y chromosome exhibited two signals each for SRY and DYZ3, both located in the centromere region. However, no signal was detected for DYZ1, which is situated in the Yq12 heterochromatin region. Approximately 84% of the analyzed cells exhibited monosomy for the X chromosome, while the remaining 16% of cells displayed an X, idic(Yp) configuration.

## Discussion

A karyotype with isodicentric Y chromosome is a common abnormal structural rearrangement between sister chromatids and is unstable during cell division; therefore, it is highly likely that various cell lines will be generated, including 45,X and del(Y) cell lines (12). The idic(Y) chromosome shows a wide variety of phenotypic symptoms, based on the proportion of mosaicism and due to breakage and fusion of idic(Y) chromosome (12). Loss of Y chromosome typically occurs through nondisjunction during meiosis or during the anaphase stage prior to fertilization, although such events are extremely rare. Post-fertilization events play an important role in interchromosomal rearrangements and anaphase lag during mitosis, contributing to the loss of structurally abnormal Y chromosome.

It has been widely believed that all individuals with a 45,X karyotype at birth would exhibit some degree of mosaicism, indicating the presence of a cryptic normal (XX or XY) cell line alongside the 45,X cell line (13). True hermaphrodites are individuals with male phenotype in the gonads and a combination of testicular and ovarian tissue. In these patients, the karyotype is typically 46,XX despite the presence of male external genitalia. This condition, known as "XO male" or "XO with testicles", is quite rare characterized by 45,X karyotype (12). The 45,X/46,XY karyotype represents a broad spectrum of phenotypes, ranging from Turner syndrome in females to phenotypically normal males with varying degrees of genital ambiguity (2). The appearance of streak gonads, ovotestes, and other histological abnormalities has been studied in several cases (1, 14).

The present case was found to have a mosaic karyotype of three cell lines of 45,X[44]/46,X, idic(Y)[1]/46,XY (5). The GTG banding method was employed to identify and analyze the chromosomal patterns, while the FISH studies conducted further confirmed the proportions of these cell lines. The phenotypic male exhibited a higher proportion of monosomic 45,X cell line in his karyotype, with a lower proportion of idic(Yp) and 46,XY cell lines. No cases of this mosaic condition have been reported in postnatal peripheral blood from adults. However, several studies have investigated prenatal testing of amniotic fluid, revealing karyotypes such as "45,X [15]/46,X, idic(Yp) [6]/46,X, ?del(Y)(q12) [2]/47,X, ?del(Y)(q12) + ?del(Y)(q12) [2], Fetal heart 45,X [12]/46, X, idic(Yp)[9]/46,X, ?del(Y)(q12)[4], Fetal kidney

45,X [19]/46,X,idic(Yp) [3]/46,X,?del(Y)(q12)[2]/47,X, ?del(Y)(q12) +?del(Y)(q12) [1]" in fetal kidney samples. However, terminating the fetus has been observed as a clinical outcome (15). The structural abnormalities of the Y chromosome and its phenotypic effect are highly diverse and variable. These variations can be attributed to the different locations of the breakpoints and the distribution of 45,X cells across various tissues (16-18). Our case study revealed a higher proportion of the monosomic 45,X cell line, which can be attributed to mitotic instability of the idicY and deleted Y chromosome. Despite being phenotypically male, the patient exhibited azoospermia. Y chromosome contains the sex-determining region Y protein (SRY) located at Yp11.3 region. Additionally, the long arm of the Y chromosome harbors several genes that are associated with spermatogenesis. Loss of azoospermia factor [AZF (a, b, c)] at Yq11.22-23 region is known to be associated with azoospermia and oligospermia. Azoospermia and infertility seen in patients with idicY chromosomes were mainly linked with Yq breakpoints. These Yq breakpoints can result in the loss and rearrangement of azoospermia factors (AZF). In general, establishing a precise relationship between genotype and phenotype remains challenging. However, some researchers have indicated that azoospermia can be observed in patients without AZF deletions, potentially due to other structural abnormalities of the Y chromosome or mosaicism (19). When idic(Y) chromosomes are detected in the affected patients, medical treatments should be considered and recommended (20). Some studies have reported cases of ambiguous genitalia during prenatal diagnosis involving 46,X/idicY karyotypes (21), whereas our study showed an adult displaying characteristics indicative of true hermaphroditism, including a micropenis and azoospermia. Furthermore, the individual exhibited an abnormal karyotype comprising three cell lines.

### Conclusion

The phenotypic manifestation of mosaicism depends on the relative proportion of each cell line. Therefore, it is important to investigate and analyze various tissues to assess the mosaic condition and to understand its influence on sexual differentiation, phenotypic appearance, development, and growth. Multiple studies have shown that mosaicism with abnormal sex chromosomes could exhibit various abnormal phenotypes including am-

biguous external genitalia, azoospermia, or Turner syndrome. A comprehensive review of many cases provides a deeper understanding of the physiology and phenotypic spectrum of the condition. Hence, conducting a detailed study by conventional karyotyping followed by FISH studies will help to detect low mosaicism involving idic(Y) and deletion of Y chromosomes. This information is vital for offering appropriate genetic counseling and managing the patients effectively.

### Acknowledgement

We would like to express our gratitude to Nitte University for providing the facility needed for the study.

### Conflict of Interest

The authors have no conflicts of interest relevant to this article.

### References

1. Telvi L, Lebbar A, Del Pino O, Barbet JP, Chausain JL. 45,X/46,XY mosaicism: report of 27 cases. *Pediatrics*. 1999;104(2 Pt):304-8.
2. Ketheeswaran S, Alsbjerg B, Christensen P, Gravholt CH, Humaidan P. 45,X/46,XY Mosaicism and normozoospermia in a patient with male phenotype. *Case Rep Med*. 2019;2019:2529080.
3. Layman LC, Tho SP, Clark AD, Kulharya A, McDonough PG. Phenotypic spectrum of 45,X/46,XY males with a ring Y chromosome and bilaterally descended testes. *Fertil Steril*. 2009;91(3):791-7.
4. Mohammadpour Lashkari F, Sadighi Gilani MA, Ghaheri A, Zamanian MR, Borjian Boroujeni P, Mohseni Meybodi A, et al. Clinical aspects of 49 infertile males with 45,X/46,XY mosaicism karyotype: a case series. *Andrologia*. 2018;50(5): e13009.
5. Akinsal EC, Baydilli N, Bayramov R, Ekmekcioglu O. A rare cause of male infertility: 45,X/46,XY mosaicism. *Urol Int*. 2018;101(4):481-5.
6. Jacobs PA, Ross A. Structural abnormalities of the Y chromosome in man. *Nature*. 1966;210(5034): 352-4.
7. Hsu LY. Phenotype/karyotype correlations of Y chromosome aneuploidy with emphasis on structural aberrations in postnatally diagnosed cases. *Am J Med Genet*. 1994;53(2):108-40.
8. Pasantes JJ, Wimmer R, Knebel S, Munch C, Kelbova C, Junge A, et al. 47,X,idic(Y),inv dup(Y): a non-mosaic case of a phenotypically normal boy with two different Y isochromosomes and neocentromere formation. *Cytogenet Genome Res*. 2012; 136(2):157-62.

9. Robinson DO, Dalton P, Jacobs PA, Mosse K, Power MM, Skuse DH, et al. A molecular and FISH analysis of structurally abnormal Y chromosomes in patients with turner syndrome. *J Med Genet.* 1999; 36(4):279-84.
10. Bergeron MB, Brochu P, Lemyre E, Lemieux N. Correlation of intercentromeric distance, mosaicism, and sexual phenotype: molecular localization of breakpoints in isodicentric Y chromosomes. *Am J Med Genet A.* 2011;155A(11):2705-12.
11. Sarrate Z, Vidal F, Blanco J. Role of sperm fluorescent in situ hybridization studies in infertile patients: indications, study approach, and clinical relevance. *Fertil Steril.* 2010;93(6):1892-902.
12. Yang Y, Hao W. Clinical, cytogenetic, and molecular findings of isodicentric Y chromosomes. *Mol Cytogenet.* 2019;12:55.
13. Forabosco A, Carratu A, Assuma M, Pol AD, Du-trillaux B, Cheli E. Male with 45,X karyotype. *Clin Genet.* 1977;12(2):97-100.
14. Cools M, Pleskacova J, Stoop H, Hoebeke P, Van Laecke E, Drop SL, et al. Gonadal pathology and tumor risk in relation to clinical characteristics in patients with 45, X/46, XY mosaicism. *J Clin Endocrinol Metab.* 2011;96(7):E1171-80.
15. Bernstein R, Steinhaus KA, Cain MJ. Prenatal application of fluorescent in situ hybridization (FISH) for identification of a mosaic Y-chromosome marker, IDIC (Yp). *Prenatal Diagn.* 1992;12(9):709-16.
16. Hernando C, Carrera M, Ribas I, Parear N, Baraibar R, Egocue J, et al. Prenatal and postnatal characterization of Y chromosome structural anomalies by molecular cytogenetic analysis. *Prenat Diagn.* 2002;22(9):802-5.
17. Kotzot D, Dufke A, Tzschach A, Baeckert-Sifeddine IT, Geppert M, Holland H, et al. Molecular breakpoint analysis and relevance of variable mosaicism in a woman with short stature, primary amenorrhea, unilateral gonadoblastoma, and a 46,X, del (Y)(q11)/45,X karyotype. *Am J Med Genet.* 2002;112(1):51-5.
18. DesGroseilliers M, Beaulieu Bergeron M, Brochu P, Lemyre E, Lemieux N. Phenotypic variability in isodicentric Y patients: study of nine cases. *Clin Genet.* 2006;70(2):145-50.
19. Jiang Y, Wang R, Li L, Xue L, Deng S, Liu R. Molecular cytogenetic study of de novo mosaic karyotype 45,X/46,X,i(Yq)/46,X,idic(Yq) in an azoospermic male: case report and literature review. *Mol Med Rep.* 2017;16(3):3433-8.
20. Guevarra FM, Nimkarn S, New MI, Lin-Su K. Long-term growth hormone therapy in an adolescent boy with 45,X/46,X,idicY(p11). *J Pediatr.* 2009;155(5):752-5.e1-3.
21. Bruyere H, Speevak MD, Winsor EJ, de Freminville B, Farrell SA, McGowanJordan J, et al. IsodicentricYp: prenatal diagnosis and outcome in 12 cases. *Prenat Diagn.* 2006;26(4):324-9.